



PATIENT

Blanca Arthaud

SPECIES

Feline

BREED

Siamese

SEX

Female Spayed

AGE

4.11 years

WEIGHT

12lbs

INTERPRETED BY

Maggie Machen Lamy,
DVM, DACVIM
(Cardiology)

IMAGING PERFORMED BY

Amanda Crook, SDEP

HOSPITAL NAME

River Edge Pet Medical
Center

REFERRING VET

Dr. Young

INVOICE

47646

DATE

4/22/26

PRESENTING CLINICAL SIGNS

History: Grade 2-3/6 heart murmur. BP: 132, 132, 186, 178mmHg. Assess prior to dental.

ELECTROCARDIOGRAPHIC FINDINGS

A six lead ECG is available at 25mm/s; 10mm/mV. The average heart rate is 140bpm. The rhythm is sinus in origin, with a p for every QRS complex and vice versa. The P wave morphology is positive with a normal dimension. Normal PR. The QRS morphology is positive with normal dimension. MEA is normal. No ectopic beats, pauses or dysrhythmias observed. ECG diagnosis: Normal sinus rhythm.

ECHOCARDIOGRAM FINDINGS

2D, m-mode, color flow and doppler imaging is available. The left ventricular wall is normal in dimension. There is a mildly hyperechoic endocardium consistent with age-related fibrosis. Mild remodeling. The papillary muscles are hyperechoic yet normal in size. The left atrium is normal in size. The right atrium is normal in size. The right ventricle appears normal. The mitral valve is normal in structure and mobility. No MR or SAM identified. The tricuspid valve appears normal in structure and mobility. No TR. Blood flow through both the LVOT and RVOT are normal in velocity. No AI/PI seen. No effusions. No obvious cardiac tumors.

CARDIAC CHART

| FELINE CARDIAC PARAMETERS | BODY WEIGHT (kg) | HR (BPM) | IVSd (cm) (Moise, Pipers) | LVIDd (cm) (Moise, Pipers) | LVWd (cm) (Moise, Pipers) | FS (%) | EF (%) |
|--|------------------|---------------------------------|--|----------------------------|---------------------------|----------------|-------------|
| NORMAL PARAMETER | ----- | 150-240 | 0.35-0.55 | <2 (mean 1.5) | 3.5-0.55 | 35-67 | 80-100 |
| PATIENT | 5.4 | NM | 0.48 | 1.5 | 0.48 | 44 | 80 |
| FELINE CARDIAC PARAMETERS | LA/AO (Boon) | LA/AO HEART BASE (Swe) (Abbott) | LA 2D short axis Base view (cm) (Abbott) | | LVOT VEL (m/s) | RVOT VEL (m/s) | E max (m/s) |
| NORMAL | <1.5 | <1.3 | <1.2 | | <1.6 | <1.3 | <0.9 |
| PATIENT | 1.3 | 1.2 | 1.2 | | 0.8 | 1.0 | NM |
| <p><i>*Note: All measurements based upon multi-modal images and methods. An average value is reported.</i> Adapted from June Boon, Veterinary Echocardiography, 1998 Abbott J & MacLean H JVIM 2006;20: 111-119, Moise et al. Am J Vet Res 47:1476, 1986. Pipers et al. Am J Vet Res 40:882, 1979.</p> | | | | | | | |

INTERPRETATION OF THE FINDINGS & FURTHER RECOMMENDATIONS

Overtly normal cardiac structure and function. No LV hypertrophy is seen, ruling out HCM. No significant valve leaks are noted, and flow through the great vessels is normal in velocity. No definitive cause for the murmur is identified in this study, making it likely physiologic in origin (i.e. secondary to tachycardia, volume changes, etc.). The ECG is unremarkable with a normal sinus rhythm.



PATIENT

Blanca Arthaud

SPECIES

Feline

BREED

Siamese

SEX

Female Spayed

AGE

4.11 years

WEIGHT

12lbs

INTERPRETED BY

Maggie Machen Lamy,
DVM, DACVIM
(Cardiology)

IMAGING PERFORMED BY

Amanda Crook, SDEP

HOSPITAL NAME

River Edge Pet Medical
Center

REFERRING VET

Dr. Young

INVOICE

47646

DATE

4/22/26

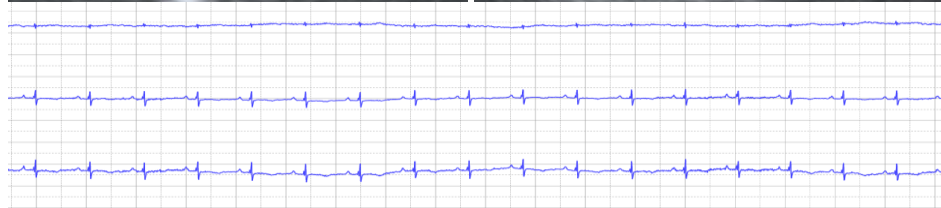
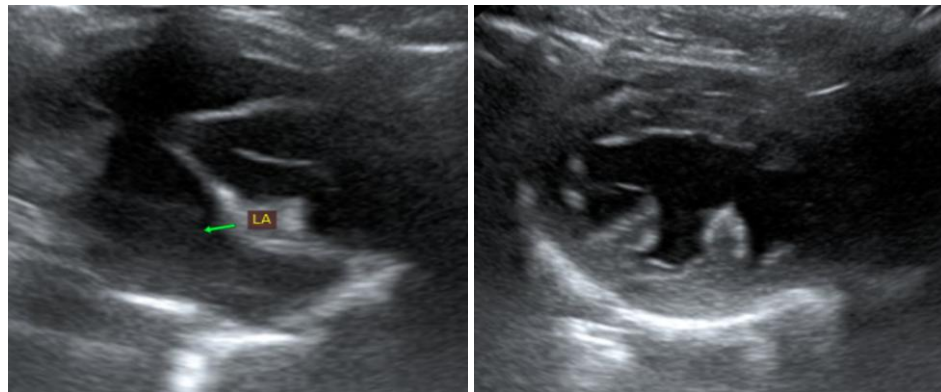
Given these findings and a normal LA dimension, no medications are indicated. Prognosis is open.

No cardiac contraindication for general anesthesia. Risk for complication with steroid or fluid use typically follows LA dilation, which in this case is low. That said, any cat can experience acute intolerance and monitoring for this phenomenon is always advised (a change in RR/RE, particularly during the initiation phase).

Monitor at home for signs of cardiac compromise, including respiratory changes and/or signs of a blood clot event (paralysis, neurologic changes).

Recommend recheck echocardiogram in 1 year to assess for any progressive issues or development of disease the pre-existing murmur may mask.

IMAGES



The information and recommendations provided are based on the images presented by the referring veterinarian. No evaluation can be communicated regarding pathology that was not visible in the image/video clips provided.

Thank you for this referral. This report was generated using transcription software, and minor dictation errors may be present. If the clinical or image interpretation does not parallel your findings or if I can be of any further assistance, please contact me.

Maggie Machen Lamy, DVM
Diplomate of the American College of Veterinary Internal Medicine (Cardiology)
info@sonopath.com